Treatment of a bifurcation lesion

Clinique Pasteur – Toulouse, France

A bifurcation lesion

Our patient today…

Gender: Male

Age: 82

Size: 176cm

Weight: 90kg

BMI: 29kg/m^2

Clinical presentation

Exertional dyspnea, NYHA II

ECG

- Sinus rhythm, normal ST segment, normal T waves

A bifurcation lesion

Male, 82

Risk factors

Hypertension

NIDD

Dyslipidemia

Former smoker status

Clinical history

1992: laryngeal cancer, surgical treatment

2016: prostate cancer, external beam radiotherapy and hormone therapy, multiple episodes of haematuria in 2017

Lifestyle

Active lifestyle

Laboratory investigations

Hb: 13.2 g/dl

Platelets: 191 G/l

TP: 100 %

HbA1C: 7.2%

Creatinine: 92 µmol/l

Creatinine clearance: 67 ml/min

Non-invasive evaluation

CT coronary angiogram

Severe stenosis of the mid-LAD and the ostium of the first diagonal branch

Baseline angiography

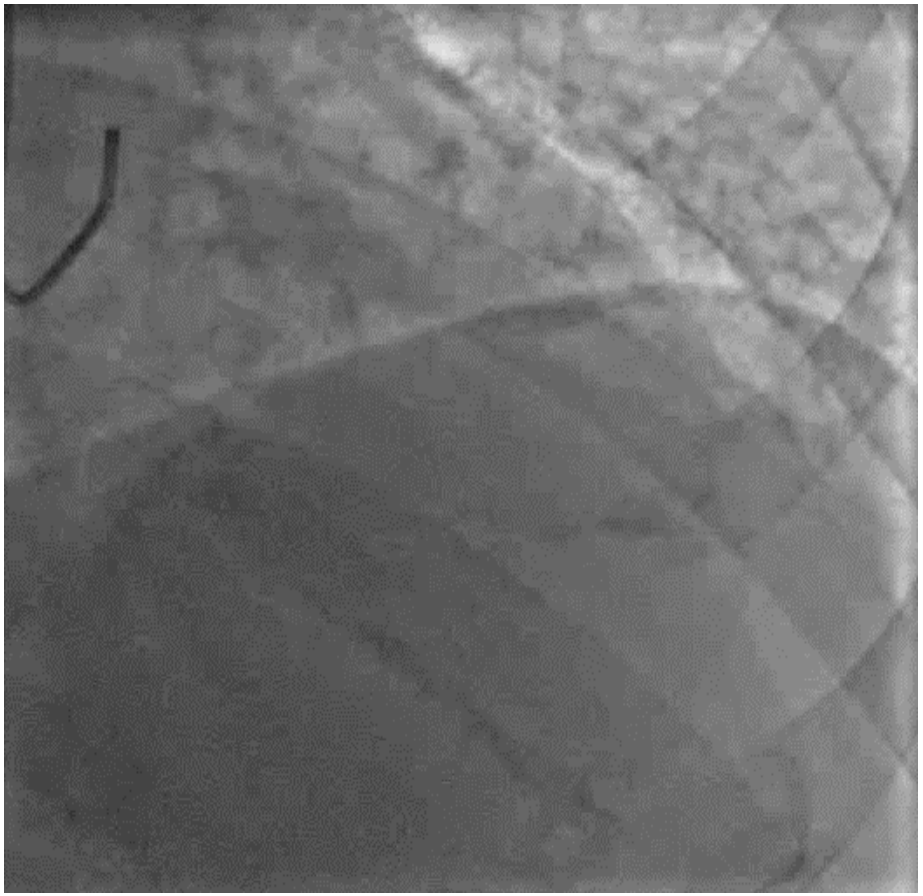

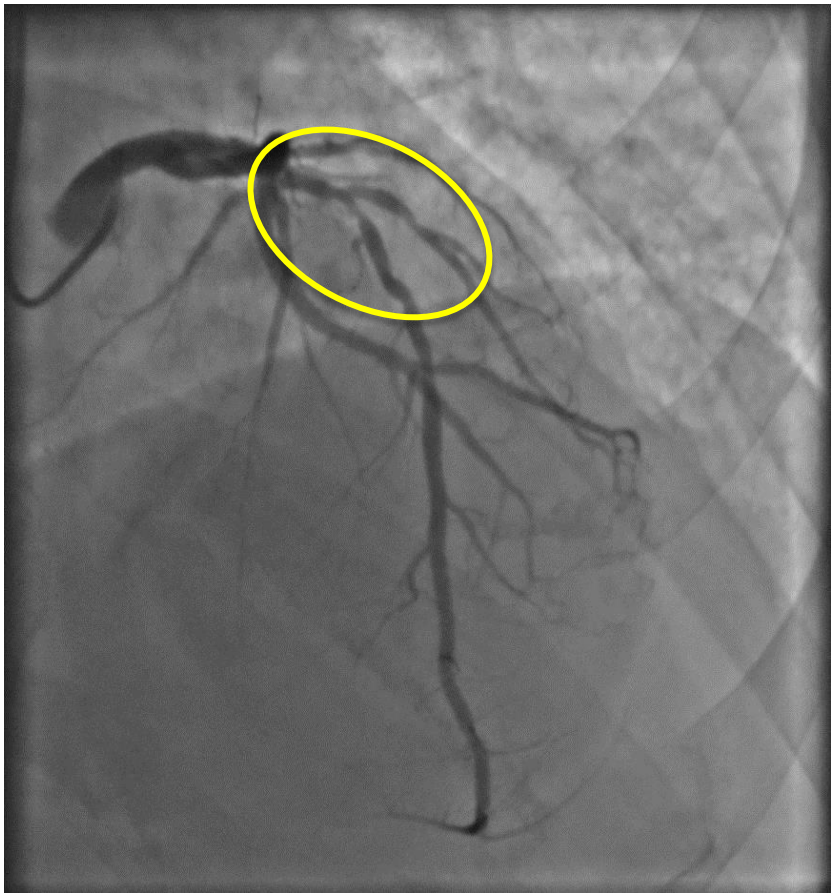

Baseline angiography

Key clinical data & angiographic reference

82 year-old diabetic patient

High bleeding risk

Treatment of a bifurcation LAD Diagonal lesion

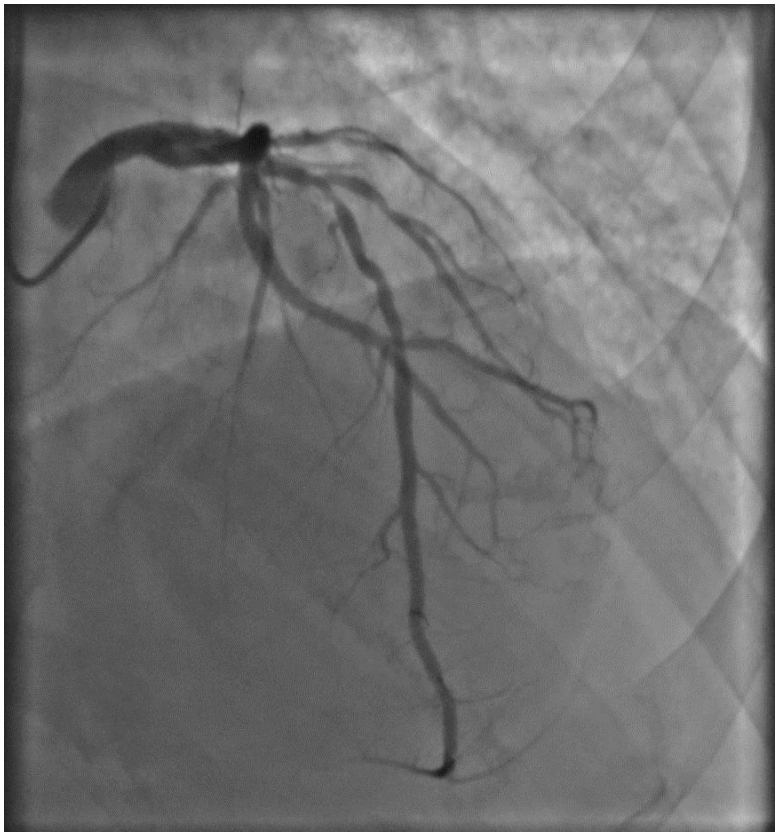

PCR